JMI Jurnal Multidisiplin Indonesia
Volume 5 Number 11, November 2026
pp. 3056-3065
E-ISSN: 2964-9048
DOI: 10.58344/jmi.v5i9.2902

Non-Asthmatic Eosinophilic Bronchitis as a Cause of Corticosteroid-Responsive Chronic Cough: A Review of Pathogenesis, Diagnosis, and Management

Arif Syafa'at*, Masrul Basyar, Dessy Mizarti
Universitas Andalas Padang, Indonesia
Email : arif.syafaat@gmail.com*

Keywords:
Eosinophilic bronchitis. Non-asthmatic eosinophilic bronchitis. Phlegm. Chronic cough.

This is an open access article under the CC BY-SA license.

Copyright © 2026 by Author. Published by Riviera Publishing

Abstract

Nonasthmatic eosinophilic bronchitis (NAEB) is characterized by a persistent, predominantly dry or minimally productive cough in the absence of variable airflow obstruction or airway hyperresponsiveness. The condition may follow a recurrent or persistent course, and some patients may subsequently develop asthma or chronic obstructive pulmonary disease (COPD), although the risk of progression remains uncertain. NAEB is estimated to account for approximately 5%–30% of chronic cough cases evaluated in specialist settings. Exposure to environmental allergens and occupational irritants has been implicated as a potential contributing factor, although its precise etiology and underlying mechanisms remain incompletely understood. NAEB shares several inflammatory features with asthma, including eosinophilic airway inflammation and increased inflammatory mediator activity. However, differences in the distribution of airway inflammation, airway remodeling, and the involvement of interleukin-13 (IL-13) and prostaglandin E2 (PGE2) may contribute to their distinct clinical characteristics. Induced sputum analysis demonstrating airway eosinophilia is the reference standard for diagnosis, while fractional exhaled nitric oxide (FeNO) may serve as a supportive biomarker but cannot reliably establish or exclude NAEB independently. Inhaled corticosteroids (ICS) remain the first-line treatment, although the optimal agent, dosage, and treatment duration have not been definitively established. Longer treatment courses may be associated with lower relapse rates. For persistent or refractory disease, treatment adherence, inhaler technique, and alternative causes of chronic cough should be reassessed before considering adjustments to ICS therapy or additional treatments, such as leukotriene receptor antagonists or short courses of oral corticosteroids in selected patients. Biologic therapies targeting interleukin-5 (IL-5) remain investigational for NAEB, with insufficient evidence to support their routine use. Further research is needed to identify reliable diagnostic and prognostic biomarkers, establish optimal corticosteroid regimens, and evaluate the efficacy and safety of second-line therapies through controlled clinical trials.

INTRODUCTION

Chronic cough, defined as a cough lasting more than eight weeks in adults, is a common reason for clinical consultation and requires systematic evaluation of its potential causes (Chung et al., 2022; Misono & Novaleski, 2024). Asthma, upper airway cough syndrome, gastroesophageal reflux disease (GERD), and nonasthmatic eosinophilic bronchitis (NAEB) are among the conditions considered in the differential diagnosis (Kanjanawasee et al., 2024). Although these conditions may present with similar clinical manifestations, their underlying

pathophysiological mechanisms and diagnostic characteristics differ (Brightling et al., 1999; Irwin et al., 2018; Morice et al., 2020).

NAEB is clinically significant because persistent cough may occur despite normal spirometric findings and the absence of variable airflow obstruction or airway hyperresponsiveness characteristic of asthma (Zhan et al., 2022; Zhang et al., 2025). Gibson et al. (1989) first described this condition among patients presenting with chronic cough and sputum eosinophilia without bronchial hyperresponsiveness. This observation established that eosinophilic airway inflammation may be present even when conventional pulmonary function testing yields normal results.

Previous clinical studies have demonstrated that NAEB represents an important cause of chronic cough in specialist respiratory settings. Brightling et al. reported that approximately 13% of patients referred for chronic cough were diagnosed with NAEB (Brightling et al., 1999). Studies conducted in China have also identified NAEB among patients across different age groups (Lai et al., 2017; Wei et al., 2009). These findings highlight the clinical relevance of NAEB in diverse patient populations. However, prevalence estimates derived from specialist referral centers should not be generalized to the broader population without appropriate epidemiological evidence.

A major diagnostic challenge in NAEB is the discrepancy between persistent respiratory symptoms and otherwise normal findings on routine pulmonary investigations. Induced sputum analysis can identify eosinophilic airway inflammation and remains an important diagnostic reference standard; however, its availability may be limited in routine clinical practice. Consequently, patients with persistent cough and normal spirometry may undergo repeated diagnostic evaluations without recognition of the underlying eosinophilic inflammatory phenotype (Lai et al., 2017; Morice et al., 2020). This diagnostic limitation may delay appropriate anti-inflammatory treatment and contribute to inefficient clinical management.

Existing literature has examined NAEB from several perspectives, including its inflammatory mechanisms, clinical manifestations, diagnostic biomarkers, responsiveness to corticosteroid therapy, and long-term prognosis (Diab et al., 2022; Diver et al., 2019). Nevertheless, these findings are not always integrated into a comprehensive clinical framework that facilitates diagnostic differentiation and evidence-based management. Accordingly, the research gap addressed by this review concerns the need for a clinically oriented synthesis of existing evidence rather than an absence of previous investigations into the disease's underlying mechanisms.

An integrated review is particularly relevant in health care settings where access to induced sputum testing and specialized respiratory services remains limited. Differentiating NAEB from asthma and other causes of chronic cough may reduce diagnostic misclassification, support appropriate therapeutic decisions, and facilitate more accurate interpretation of corticosteroid responsiveness. This review therefore connects established pathophysiological evidence with practical considerations for diagnosis and management while acknowledging the limitations of existing clinical research.

This narrative review aimed to synthesize current evidence regarding the etiology, pathogenesis, clinical characteristics, diagnostic approaches, treatment strategies, and prognosis of NAEB as a cause of corticosteroid-responsive chronic cough. By organizing the available literature around the clinical evaluation of persistent cough, the review sought to clarify the circumstances in which NAEB should be considered in the differential diagnosis and identify areas requiring further investigation. Particular attention was given to diagnostic accessibility, therapeutic uncertainties, and the applicability of existing evidence to clinical practice in Indonesia.

METHOD

This study employed a narrative literature review to synthesize published evidence on nonasthmatic eosinophilic bronchitis (NAEB) and chronic cough. The review included clinical guidelines, observational studies, clinical trials, meta-analyses, and relevant review articles. Foundational publications were also included to provide historical and clinical context regarding NAEB.

Relevant publications were identified through searches of PubMed/MEDLINE and Google Scholar using combinations of the terms “eosinophilic bronchitis,” “nonasthmatic eosinophilic bronchitis,” “chronic cough,” “sputum eosinophilia,” and “inhaled corticosteroids.” Articles were selected based on their relevance to the pathogenesis, clinical characteristics, diagnosis, treatment, and prognosis of NAEB.

The selected literature was synthesized thematically, focusing on airway inflammation, pulmonary function findings, diagnostic methods, therapeutic interventions, and clinical outcomes. Findings were compared across studies, with attention to differences in clinical settings, study characteristics, and methodological limitations. No quantitative meta-analysis or formal risk-of-bias assessment was performed. The findings were therefore presented as a narrative synthesis of the available evidence.

RESULTS AND DISCUSSION

Etiology and Pathogenesis

Glynn and Michaels (1960) found eosinophils in the airway mucosa of five non-smoking chronic bronchitis patients, without evaluating pulmonary function or bronchial hyperresponsiveness. Gibson et al. (1989) reported sputum eosinophilia in seven non-smoking chronic bronchitis patients, ruling out asthma, and introduced the term non-asthmatic eosinophilic bronchitis (NAEB). NAEB is characterized by chronic cough that responds to inhaled corticosteroids, accompanied by bronchial eosinophilia without airway obstruction. Patients are typically middle-aged with dry or productive cough for more than 8 weeks. Prevalence is unknown, but NAEB is estimated to affect 5-30% of chronic cough patients (Brightling, 2006; Lai et al., 2017).

The degree of eosinophilic inflammation of the airways in NAEB patients does not depend on the severity or duration of coughing. Symptoms of nasal disturbances appear in 25-60% of NAEB patients, although there is no eosinophilic inflammation based on nasal rinse results and 40-60% of patients show atopy. Studies with few patients show the prevalence of atopy varies from 0% to 90%. This prevalence rate is also found in asthma patients, but it is significantly higher than other causes of chronic cough (Brightling, 2006; Joo et al., 2002).

Exposure to allergens during activity and work may cause NAEB, although its etiology and mechanism are not yet known. Cases of NAEB have been reported as a result of exposure to dust mites, fungi, and drugs such as bucillamine and leflunomide. Approximately 44% of NAEB patients are exposed to dust mites, but the clinical implications are uncertain. Lemière et al. (1997) reported a case of exposure to acrylate at work in a female worker who coughed while working. An increase in eosinophilia in sputum was observed during working hours (0 to 13%) and during specific inhalation challenge tests (0 to 5.8%) in the absence of bronchial hyperresponsiveness. Non-asthmatic eosinophilic bronchitis due to workplace exposure (ONAEB) has been identified after exposure to various agents such as latex, flour, egg proteins, fungal spores, acrylate epoxy resins, metal liquids, chloramines, isocyanates, formaldehyde, and polymers. Isolated cough is found in about 20% of patients, although other respiratory symptoms also frequently appear. The potential development of ONAEB into occupational asthma is still unknown (Lemière et al., 1997; Wiggans & Barber, 2017; Yacoub et al., 2005).

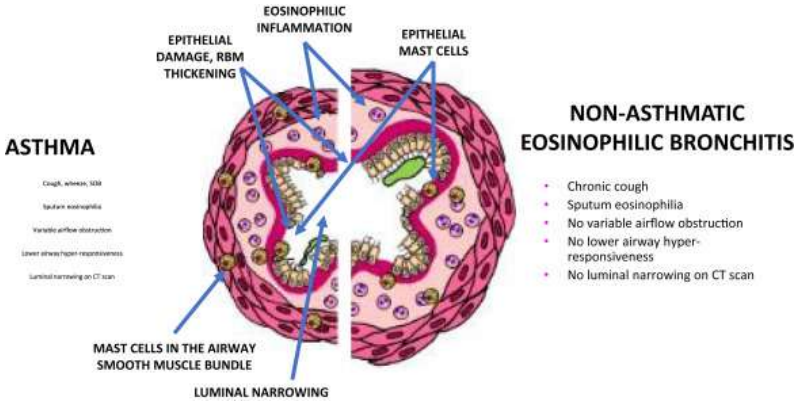

Figure 1. Overview of symptoms of asthma and eosinophilic bronchitis
Source: Original image attribution requires author verification.

NAEB exhibits immunopathological characteristics similar to asthma, such as increased eosinophilia in the sputum as well as bronchial and submucosal epithelium, thickening of the basal membrane and reticular lamina, and the formation and proliferation of blood vessels. An increase in the number of eosinophil progenitor cells and CD34+ hematopoietic progenitor cells in the blood and sputum, as well as cytokines and proinflammatory mediators in sputum such as IL-5, IL-4, IL-10, IL-2, IL-8, IFN-γ, and ECP, also occur in these two diseases. According to some researchers, the number of eosinophils in bronchoalveolar lavage is similar between these two conditions, although some have reported differences. The reason for this difference is still unknown. Radiological findings such as bronchiectasis, emphysema, and air traps are also seen in both diseases (Berry et al., 2004; Brightling et al., 2002; Park et al., 2006; Sastre et al., 2008; Zhang et al., 2021).

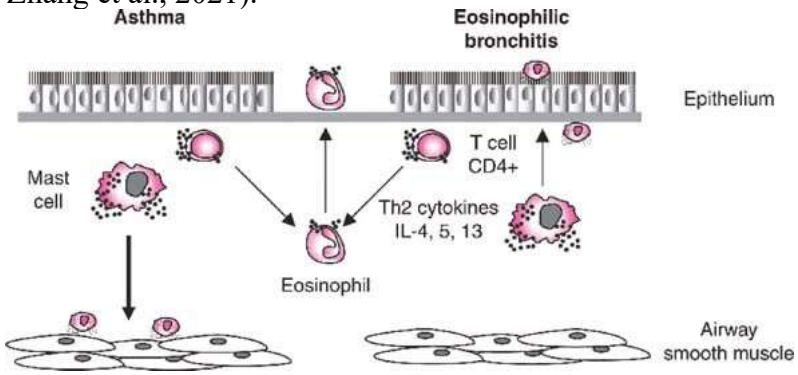

Figure 2. Pathophysiology of eosinophilic bronchitis
Source: Original image attribution requires author verification.

Clinical Picture

NAEB is known as absence of airway hyperresponsiveness in the respiratory tract, for example, a provocative concentration of methacholine is less than 16 mg/mL which leads to a 20% decrease in FEV1. This condition is also characterized by the presence of eosinophilia in sputum (>3%) in patients visiting the polyclinic with chronic cough complaints that last more than two months without symptoms or signs of airway obstruction (Brightling, 2006).

Table 1. Differences in symptoms of eosinophilic bronchitis with other causes of chronic cough

Fitur	NAEB	Asma Klasik	Varian Batuk Asma	Batuk Atopik
Gejala	Ini terkait dengan pernapasan	Sesak napas, batuk, mengi	Batuk terisolasi	Batuk terisolasi

Atopi	bagian atas / gejala saluran Mirip dengan populasi umum	Sering terjadi	Sering terjadi	Sering terjadi
Hiperresponsivitas saluran pernapasan	Tidak ada	Tidak ada	Tidak ada	Tidak ada
Hipersensitivitas refleks batuk	Meningkat	Normal atau meningkat	Normal atau meningkat	Meningkat
Respon bronkodilator	Tidak ada	Ya	Ya	Tidak ada
Respon terhadap kortikosteroid	Ya	Ya	Ya	Ya
Sputum eosinofilia	Selalu	Biasanya	Biasanya	Biasanya
Biopsi bronkial eosinofilia	Cukup sering	Sering terjadi	Sering terjadi	Sering terjadi
Sel mast dalam kumpulan otot polos saluran napas	Tidak ada	Ya	Ya	Tidak diketahui

Source: Adapted from Brightling (2006) and Diver et al. (2019).
Note: NAEB = non-asthmatic eosinophilic bronchitis; *with sputum eosinophilia.

Increased nitric oxide levels in exhaled air occurred without PEF variability. Cough in these patients usually responds well to inhaled and/or oral corticosteroid treatment. Patients are generally middle-aged, with no history of smoking and atopy, with the primary complaint of chronic cough. Current literature studies suggest that the sensitivity of the cough reflex in NAEB affects coughing, and eosinophilic inflammation is associated with increased sensitivity of the cough reflex. Cough severity, increased cough reflex sensitivity (C5 <3.9 mM), and ratio of eosinophils in sputum decreased with inhaled and/or oral corticosteroid therapy. Research by Park et al. (2004) suggests that recurrence of eosinophilia in sputum (3%) in asymptomatic periods indicates that chronic cough in NAEB patients is not necessarily associated with eosinophilic inflammation.

Diagnosis

Patients with chronic cough need to have an medical history of smoking habits, environmental/occupational evaluation, and medication. Physical examinations, including nasopharyngoscopy and reflux history, as well as chest radiography evaluation, spirometry, bronchial provocation tests, sputum cell count, and nitric oxide levels in expiratory air should also be performed. Additional tests include sinus imaging, 24-hour endoscopy or esophageal pH, thoracic CT scan, bronchoscopy, and cardiac examination (Irwin et al., 2018; Morice et al., 2020).

The diagnosis of NAEB is made based on an medical history, clinical, radiological, and spirometry examinations as well as evaluation of inflammation of the lower airways. Sputum analysis is the primary method in the diagnosis of NAEB because it more accurately indicates eosinophilia of the airways. Airway inflammation can be assessed by sputum induction, a simple, reliable, and non-invasive method. Adequate sputum can be obtained from the lower airways in 80% of adults and children by administration of hypertonic salts through a nebulizer. Hypertonic salts are considered effective for induction by increasing fluid flow from the airway epithelium, stimulating cough receptors, or improving mucociliary clearance (Belda et al., 2000; Brightling, 2006).

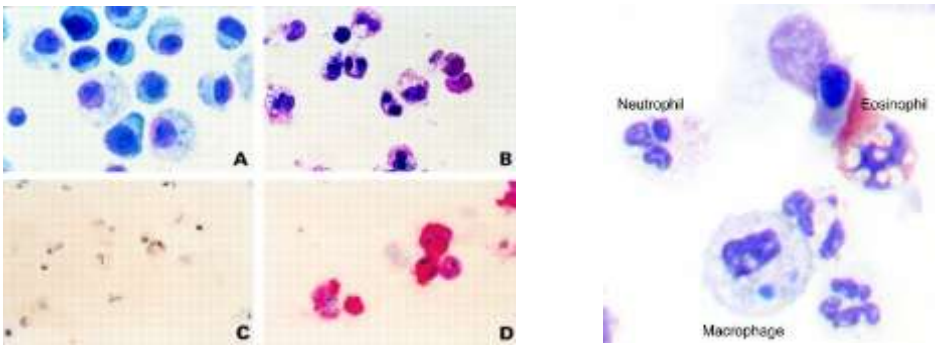

Figure 3. Eosinophils on sputum examination
Source: Original image attribution requires author verification.

The fractional exhaled nitric oxide measurement (FeNO) can also be used as a biomarker for the identification of eosinophilic inflammation of the airways, nitric oxide levels in expiratory air can be measured before switching to invasive methods such as bronchial lavage. In asthma patients, elevated levels of NO in expiratory air are used as markers of airway inflammation and to assess disease control as well as the effectiveness of anti-inflammatory therapies. Although low levels of NO in expiratory air may rule out the diagnosis of NAEB in patients with chronic non-asthmatic cough, the role of NO in NAEB is still unclear (Oh et al., 2008; Villalobos-Violán et al., 2022).

A meta-analysis by Song et al. (2017) of 15 studies involving 2,087 cases found that fractional measurements of exhaled nitric oxide (FeNO) had moderate diagnostic accuracy in asthma cough variants, but were lower in NAEB. Therefore, FeNO measurements may not be useful for predicting NAEB diagnosis. Yu et al. (2010), in their study involving 109 cases, compared the potential cause of chronic cough with a definitive diagnosis. They found that there was a 27.5% discrepancy between the two and suggested that starting treatment based on probable causes could be an effective solution in dealing with these cases.

Chest radiography is primarily used to investigate alternative causes of chronic cough; a normal radiograph does not exclude NAEB. Imaging findings should not be treated as diagnostic for NAEB without corresponding clinical and inflammatory evidence (Brightling, 2006).

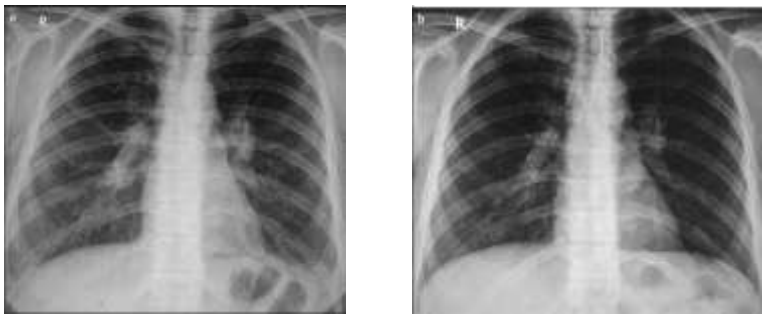

Figure 4. Chest radiograph in patients with eosinophilic bronchitis
Source: Original image attribution requires author verification.

In patients with eosinophilic bronchitis, airway obstruction occurs with a normal response. This condition, characterized by eosinophilia in the bronchoalveolar rinse or peripheral eosinophilia, is increasingly recognized as a common cause of chronic cough. Patients usually respond well to inhaled corticosteroids. CT scans show that the walls of the bronchi will appear thicker than normal. This is caused by chronic inflammation that leads to increased mucus production and structural changes in the walls of the bronchi. The airways may appear narrower due to the thickening of the bronchial walls leading to a decrease in the area of the airways (Park et al., 2006).

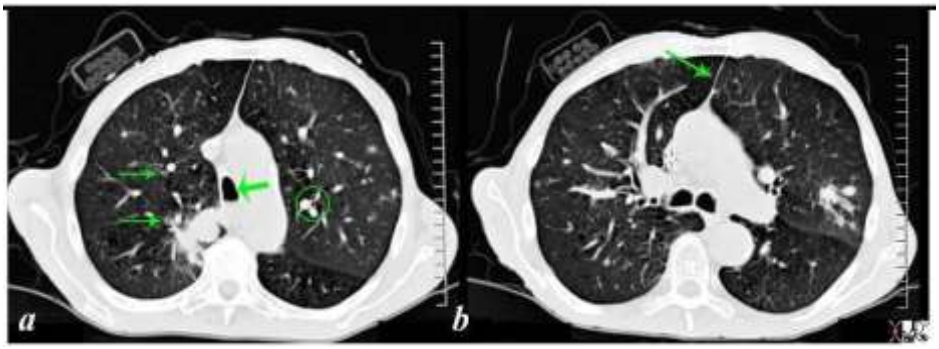

Figure 5. Thoracic CT scan of a patient with eosinophilic bronchitis
Source: Original image attribution requires author verification.

Discussion

Management

The main treatment for patients with non-asthmatic eosinophilic bronchitis is anti-inflammatory therapy which includes inhaled corticosteroids. If inflammation arises as a result of occupational exposure or inhaled allergens, it is necessary to take protective measures. The use of budesonide 400 μg twice daily or fluticasone at equivalent doses for 4 weeks has been shown to be effective in relieving symptoms and reducing eosinophils in the sputum. It is not yet clear whether this therapy should be discontinued in patients who have achieved symptom control. Recurrent sputum eosinophilia is found in patients whose symptoms improve with treatment. Mixed responses to inhaled corticosteroid therapy suggest that there are different mechanisms that may play a role in the pathology of the disease (Côté et al., 2020; Zhan et al., 2019).

The use of oral corticosteroids may be necessary in cases of cough that do not respond to high-dose inhaled corticosteroid treatment and eosinophilic inflammation. In recent years, leukotriene receptor antagonists have been proposed as potential therapeutic agents for the treatment of NAEB. The study by Cai et al. (2012) in patients who have never used steroids showed that montelukast (10 mg/day) administered with inhaled corticosteroids (400 μg/day) had antitussive and anti-inflammatory effects similar to high-dose inhaled corticosteroid therapy (800 μg/day), and highlighted the possible role of cys-LT in the pathogenesis of NAEB. The study by Bao et al. (2015) in 65 patients found that the combination of montelukast with budesonide was effective in improving quality of life, suppressing eosinophilic inflammation, and eliminating cough in patients with NAEB. If NAEB is left untreated, then NAEB can be temporary, episodic, or persistent, and rarely is long-term oral steroid therapy necessary in patients (Berry et al., 2005; Lai et al., 2015).

CONCLUSION

Nonasthmatic eosinophilic bronchitis (NAEB) is a chronic inflammatory airway condition characterized by eosinophilic inflammation without the variable airflow obstruction or airway hyperresponsiveness typically associated with asthma. The condition commonly presents with a persistent cough despite normal spirometric findings. Induced sputum analysis demonstrating elevated eosinophil levels, typically ≥3% of nonsquamous inflammatory cells, is considered the diagnostic reference standard for NAEB. Fractional exhaled nitric oxide (FeNO) may serve as a supportive biomarker for eosinophilic airway inflammation; however, it cannot reliably confirm or exclude NAEB independently. Inhaled corticosteroids (ICS) are the first-line treatment for reducing airway inflammation and alleviating cough. Although most patients respond favorably to ICS therapy, persistent or refractory cases may require further clinical evaluation and individualized treatment adjustments, including consideration of a short course of oral corticosteroids in selected circumstances.

FUNDING

The authors declare that no financial support was received for the conduct of this research and/or the publication of this article.

CONFLICT OF INTEREST

The authors declare that this research was conducted in the absence of any commercial or financial relationships that could be construed as a potential conflict of interest.

AUTHOR CONTRIBUTION

All authors contributed to the preparation and writing of this article.

GENERATIVE ARTIFICIAL INTELLIGENCE USAGE STATEMENT

In the preparation of this manuscript, the authors utilized Artificial Intelligence (AI) solely for the purposes of improving grammar and checking language usage.

REFERENCES

Bao, W., Liu, P., Qiu, Z., Yu, L., Hang, J., & Gao, X. (2015). Efficacy of add-on montelukast in nonasthmatic eosinophilic bronchitis: The additive effect on airway inflammation, cough and life quality. *Chinese Medical Journal, 128*(1), 39–45.

Belda, J., Leigh, R., Parameswaran, K., O'Byrne, P. M., Sears, M. R., & Hargreave, F. E. (2000). Induced sputum cell counts in healthy adults. *American Journal of Respiratory and Critical Care Medicine, 161*(2 Pt 1), 475–478.

Berry, M. A., Hargadon, B., McKenna, S., Shaw, D., Green, R. H., & Brightling, C. E. (2005). Observational study of the natural history of eosinophilic bronchitis. *Clinical & Experimental Allergy, 35*(5), 598–601.

Berry, M. A., Parker, D., Neale, N., Woodman, L., Morgan, A., & Monk, P. (2004). Sputum and bronchial submucosal IL-13 expression in asthma and eosinophilic bronchitis. *Journal of Allergy and Clinical Immunology, 114*(5), 1106–1109.

Brightling, C. E. (2006). Chronic cough due to nonasthmatic eosinophilic bronchitis: ACCP evidence-based clinical practice guidelines. *Chest, 129*(1 Suppl), 116S–121S. https://doi.org/10.1378/chest.129.1_suppl.116S

Brightling, C. E., Bradding, P., Symon, F. A., Holgate, S. T., Wardlaw, A. J., & Pavord, I. D. (2002). Mast-cell infiltration of airway smooth muscle in asthma. *New England Journal of Medicine, 346*(22), 1699–1705. https://doi.org/10.1056/NEJMoa012705

Brightling, C. E., Ward, R., Goh, K. L., Wardlaw, A. J., & Pavord, I. D. (1999). Eosinophilic bronchitis is an important cause of chronic cough. *American Journal of Respiratory and Critical Care Medicine, 160*(2), 406–410. https://doi.org/10.1164/ajrccm.160.2.9810100

Cai, C., He, M. Z., Zhong, S. Q., Tang, Y., Zhang, M., & Chen, Q. L. (2012). Add-on montelukast vs double-dose budesonide in nonasthmatic eosinophilic bronchitis: A pilot study. *Respiratory Medicine, 106*(10), 1369–1375.

Chung, K. F., McGarvey, L., Song, W.-J., Chang, A. B., Lai, K., Canning, B. J., Birring, S. S., Smith, J. A., & Mazzone, S. B. (2022). Cough hypersensitivity and chronic cough. *Nature Reviews Disease Primers, 8*, Article 45. https://doi.org/10.1038/s41572-022-00370-w

Côté, A., Russell, R. J., Boulet, L. P., Gibson, P. G., Lai, K., & Irwin, R. S. (2020). Managing chronic cough due to asthma and NAEB in adults and adolescents: CHEST guideline and expert panel report. *Chest, 158*(1), 68–96. https://doi.org/10.1016/j.chest.2020.03.018

Diab, N., Patel, M., O'Byrne, P., & Satia, I. (2022). Narrative review of the mechanisms and treatment of cough in asthma, cough variant asthma, and non-asthmatic eosinophilic bronchitis. *Lung, 200*(6), 707–716. https://doi.org/10.1007/s00408-022-00575-6

Diver, S., Russell, R. J., & Brightling, C. E. (2019). Cough and eosinophilia. *The Journal of Allergy and Clinical Immunology: In Practice, 7*(6), 1740–1747. https://doi.org/10.1016/j.jaip.2019.04.048

Gibson, P. G., Dolovich, J., Denburg, J., Ramsdale, E. H., & Hargreave, F. E. (1989). Chronic cough: Eosinophilic bronchitis without asthma. *The Lancet, 333*(8651), 1346–1348. https://doi.org/10.1016/S0140-6736(89)92801-8

Glynn, A. A., & Michaels, L. (1960). Bronchial biopsy in chronic bronchitis and asthma. *Thorax, 15*, 142–153.

Irwin, R. S., French, C. L., Chang, A. B., Altman, K. W., & CHEST Expert Cough Panel. (2018). Classification of cough as a symptom in adults and management algorithms: CHEST guideline and expert panel report. *Chest, 153*(1), 196–209. https://doi.org/10.1016/j.chest.2017.10.016

Joo, J. H., Park, S. J., Park, S. W., Lee, J. H., Kim, D. J., & Uh, S. T. (2002). Clinical features of eosinophilic bronchitis. *The Korean Journal of Internal Medicine, 17*(1), 31–37.

Kanjanawasee, D., Poachanukoon, O., Sriprasart, T., Chirakalwasan, N., Saiphoklang, N., Athipongarporn, A., Sompornrattanaphan, M., Suwanwech, T., Chotchai, N., Ruxrungtham, K., Boonsawat, W., Brannan, J. D., Song, W. J., & Pornsuriyasak, P. (2024). Chronic cough management: Practical guidelines and PICO-based evidence for treatment. *Asian Pacific Journal of Allergy and Immunology, 42*. https://doi.org/10.12932/AP-191124-1974

Lai, K., Chen, R., Peng, W., & Zhan, W. (2017). Non-asthmatic eosinophilic bronchitis and its relationship with asthma. *Pulmonary Pharmacology & Therapeutics, 47*, 66–71. https://doi.org/10.1016/j.pupt.2017.07.002

Lai, K., Liu, B., Xu, D., Han, L., Lin, L., & Xi, Y. (2015). Will nonasthmatic eosinophilic bronchitis develop into chronic airway obstruction? A prospective, observational study. *Chest, 148*(4), 887–894. https://doi.org/10.1378/chest.14-2351

Lemière, C., Efthimiadis, A., & Hargreave, F. E. (1997). Occupational eosinophilic bronchitis without asthma: An unknown occupational airway disease. *Journal of Allergy and Clinical Immunology, 100*(6 Pt 1), 852–853.

Misono, S., & Novaleski, C. K. (2024). Current opinion in refractory and/or unexplained chronic cough. *Current Opinion in Otolaryngology & Head and Neck Surgery, 32*(6), 403–409. https://doi.org/10.1097/MOO.0000000000001009

Morice, A. H., Millqvist, E., Bieksiene, K., Birring, S. S., Dicpinigaitis, P., & Domingo Ribas, C. (2020). ERS guidelines on the diagnosis and treatment of chronic cough in adults and children. *European Respiratory Journal, 55*(1), Article 1901136. https://doi.org/10.1183/13993003.01136-2019

Oh, M. J., Lee, J. Y., Lee, B. J., & Choi, D. C. (2008). Exhaled nitric oxide measurement is useful for the exclusion of nonasthmatic eosinophilic bronchitis in patients with chronic cough. *Chest, 134*(5), 990–995. https://doi.org/10.1378/chest.07-2541

Park, S. W., Lee, Y. M., Jang, A. S., Lee, J. H., Hwangbo, Y., & Kim, D. J. (2004). Development of chronic airway obstruction in patients with eosinophilic bronchitis: A prospective follow-up study. *Chest, 125*(6), 1998–2004. https://doi.org/10.1378/chest.125.6.1998

Park, S. W., Park, J. S., Lee, Y. M., Lee, J. H., Jang, A. S., & Kim, D. J. (2006). Differences in radiological/HRCT findings in eosinophilic bronchitis and asthma: Implication for bronchial responsiveness. *Thorax, 61*(1), 41–47.

Sastre, B., Fernández-Nieto, M., Mollá, R., López, E., Lahoz, C., & Sastre, J. (2008). Increased prostaglandin E2 levels in the airway of patients with eosinophilic bronchitis. *Allergy, 63*(1), 58–66.

Song, W. J., Kim, H. J., Shim, J. S., Won, H. K., Kang, S. Y., & Sohn, K. H. (2017). Diagnostic accuracy of fractional exhaled nitric oxide measurement in predicting cough-variant asthma and eosinophilic bronchitis in adults with chronic cough: A systematic review

and meta-analysis. *Journal of Allergy and Clinical Immunology, 140*(3), 701–709. https://doi.org/10.1016/j.jaci.2016.11.037

Villalobos-Violán, V., Betancor, D., Mahíllo-Fernández, I., & Sastre, J. (2022). Nonasthmatic eosinophilic bronchitis and asthma: Analysis of biomarkers. *Journal of Investigational Allergology and Clinical Immunology, 32*(3), 216–217.

Wei, W., Yu, L., Lu, H., Wang, L., Shi, C., & Ma, W. (2009). Comparison of cause distribution between elderly and non-elderly patients with chronic cough. *Respiration, 77*(3), 259–264.

Wiggans, R. E., & Barber, C. M. (2017). Metalworking fluids: A new cause of occupational non-asthmatic eosinophilic bronchitis. *Thorax, 72*(6), 579–580.

Yacoub, M. R., Malo, J. L., Labrecque, M., Cartier, A., & Lemière, C. (2005). Occupational eosinophilic bronchitis. *Allergy, 60*(12), 1542–1544.

Yu, L., Wei, W., Wang, L., Huang, Y., Shi, C., & Lü, H. (2010). Upper-airway cough syndrome with latent eosinophilic bronchitis. *Lung, 188*(1), 71–76.

Zhan, W., Tang, J., Chen, X., Yi, F., Han, L., & Liu, B. (2019). Duration of treatment with inhaled corticosteroids in nonasthmatic eosinophilic bronchitis: A randomized open label trial. *Therapeutic Advances in Respiratory Disease, 13*, Article 1753466619891520. https://doi.org/10.1177/1753466619891520

Zhang, Q., Luo, W., Zhan, W., Xie, J., Wang, H., & Chung, K. F. (2021). Non-asthmatic eosinophilic bronchitis is characterized by proximal airway eosinophilic inflammation as compared with classic asthma and cough variant asthma. *Clinical & Experimental Allergy, 51*(12), 1637–1640.

Zhan, C., Xu, R., Li, B., Liu, J., Liang, W., Zhang, S., Fang, L., Zhong, S., de Silva, S. D. S. H., & Sivapalan, D. (2022). Eosinophil progenitors in patients with non-asthmatic eosinophilic bronchitis, eosinophilic asthma, and normal controls. *Frontiers in Immunology*, *13*, 737968.

Zhang, L., Aierken, A., Dong, R., Zhang, M., Chen, Q., & Qiu, Z. (2025). Comparison of airway inflammation characteristics detected by lower exhaled nitric oxide in cough variant asthma, non-asthmatic eosinophilic bronchitis, and classic asthma. *Journal of Asthma*, *62*(5), 807–816.